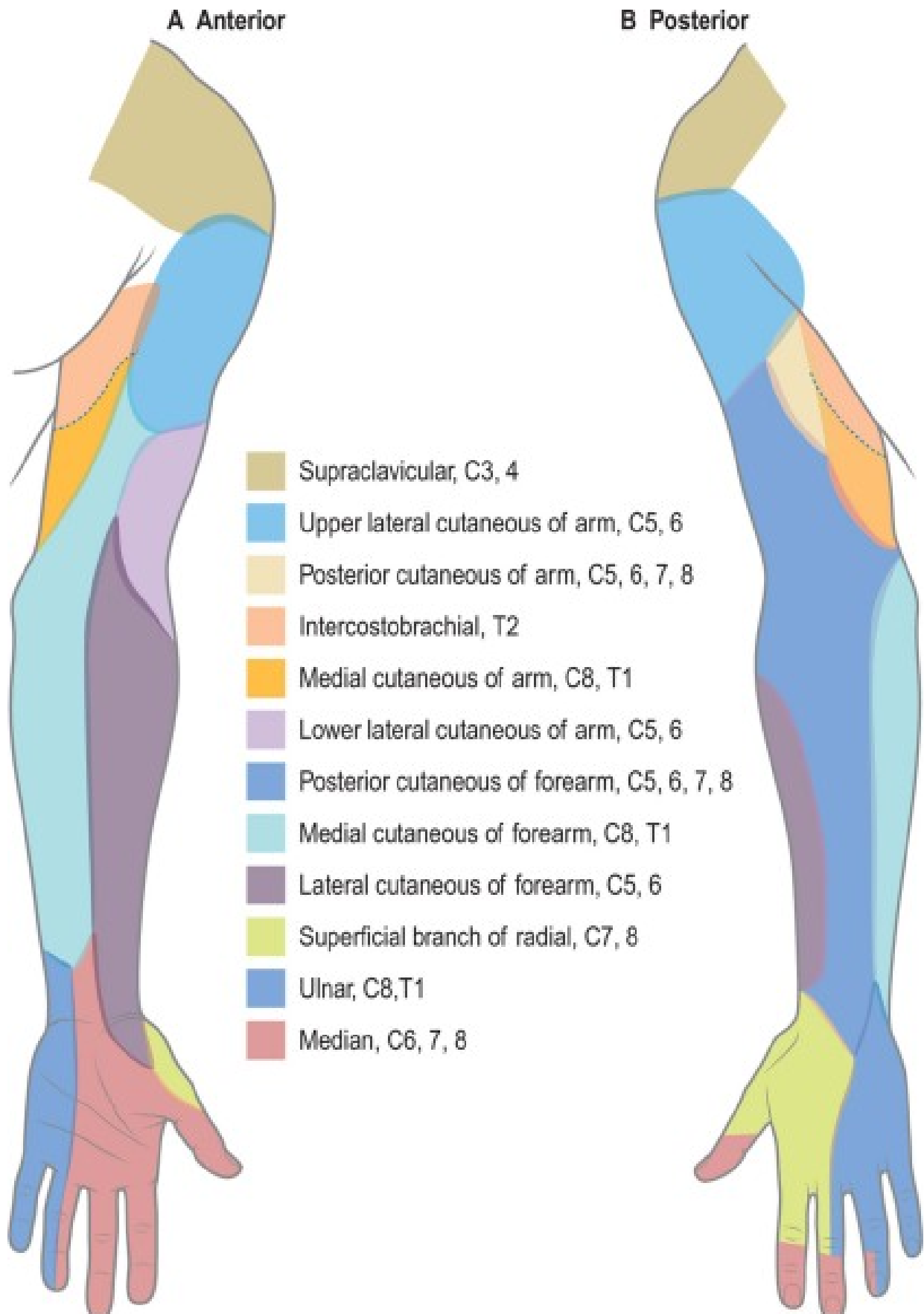
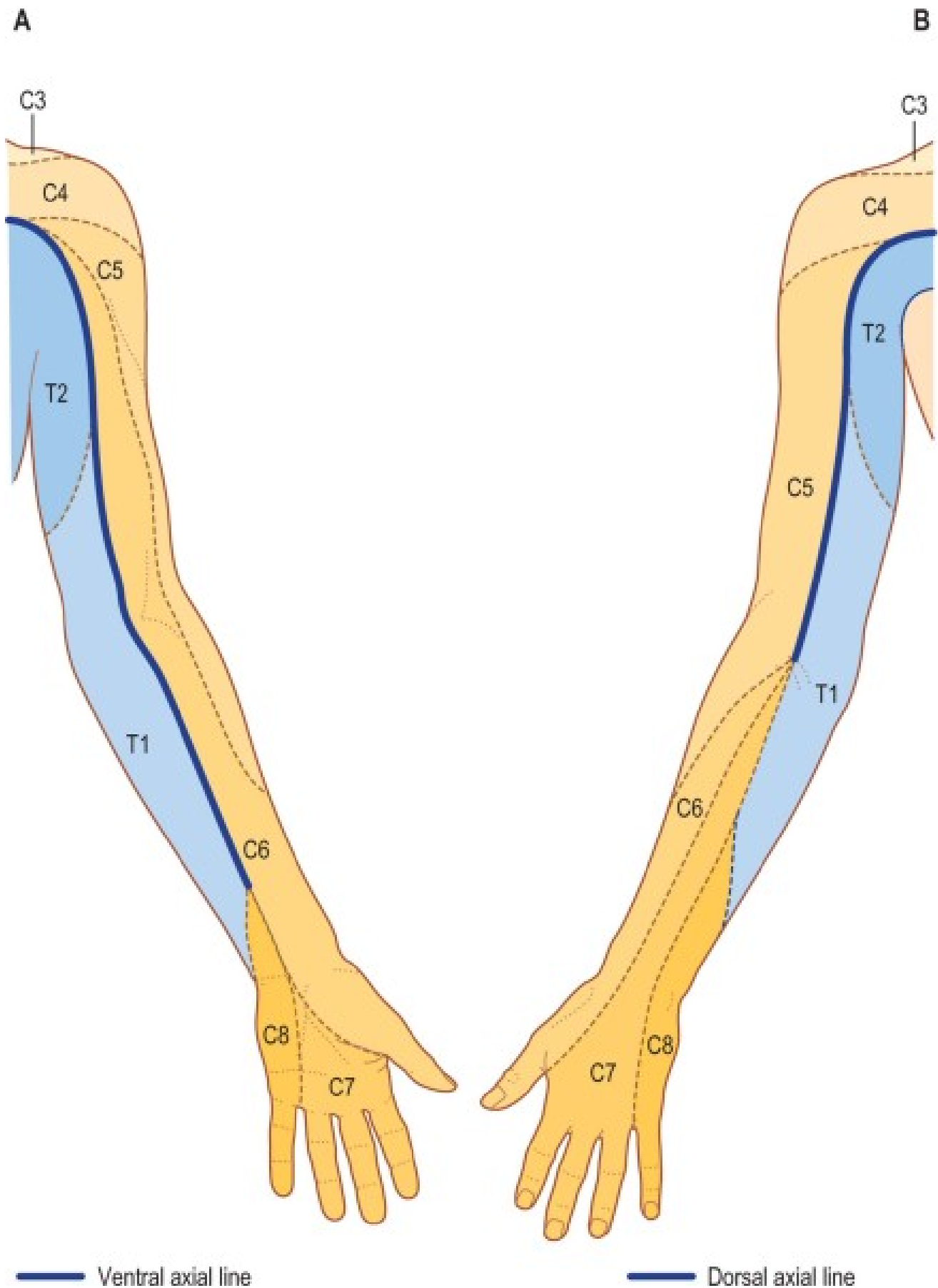


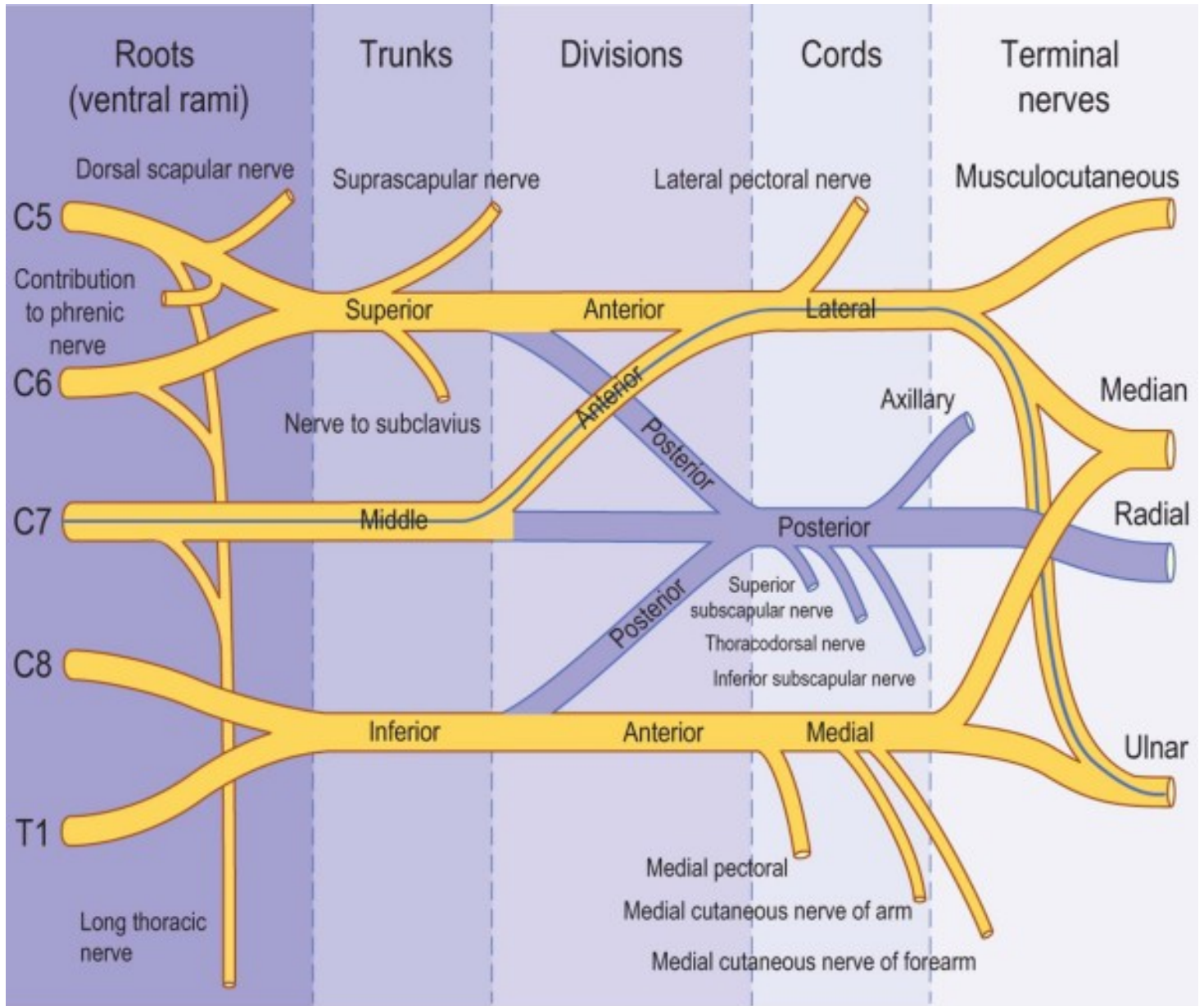
Posterior Forearm and Hand: Cutaneous Nerve Distributions



Posterior Forearm and Hand: Dermatomes



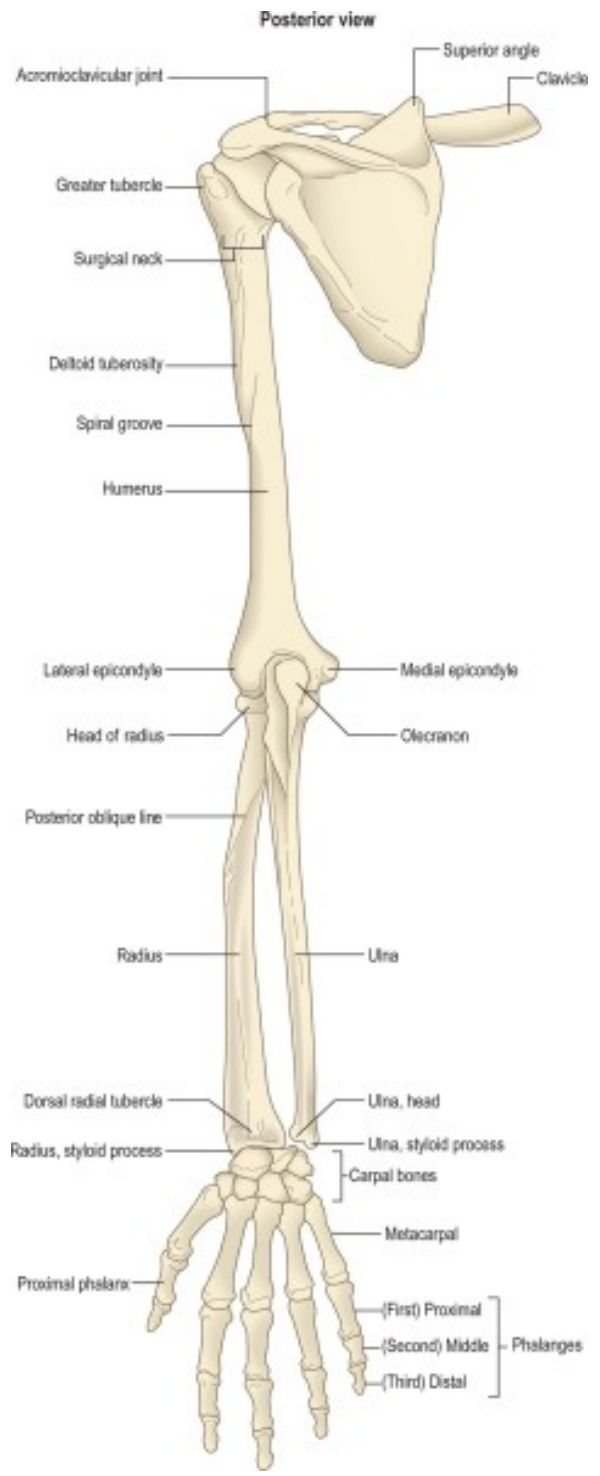
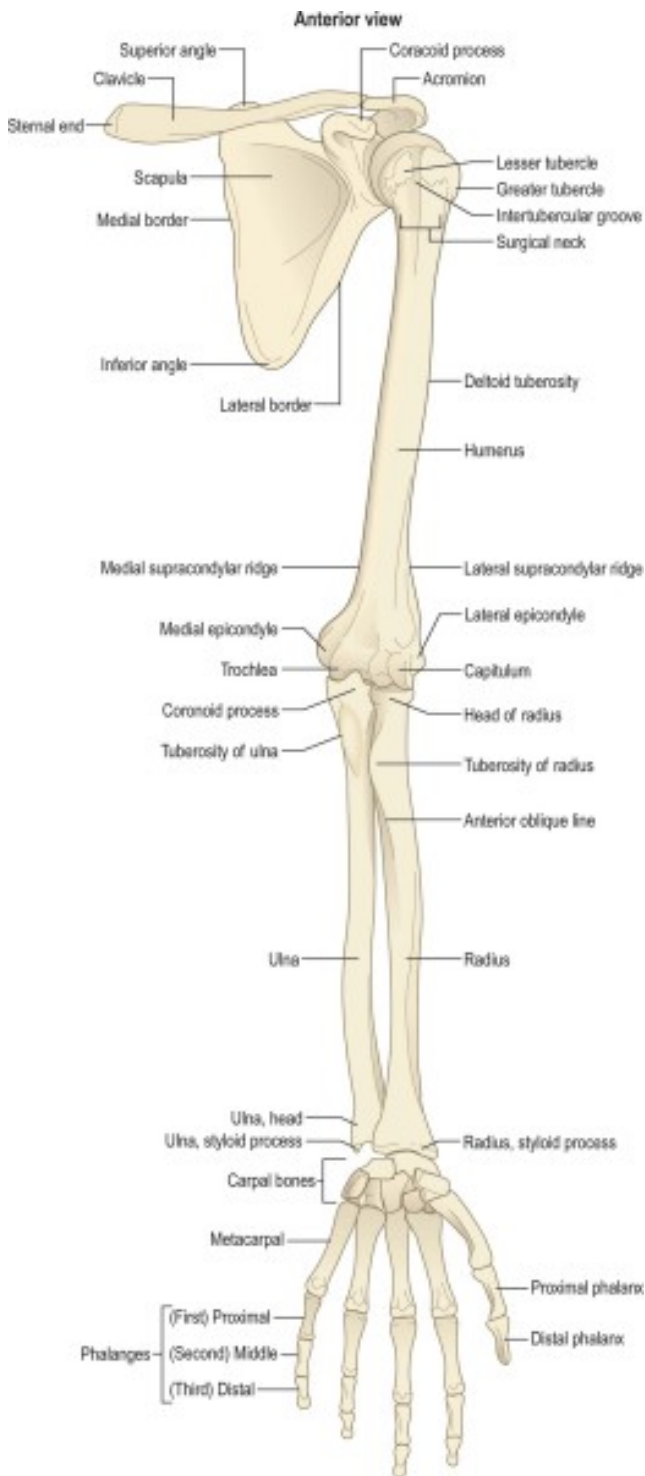
Posterior Forearm and Hand: Brachial Plexus



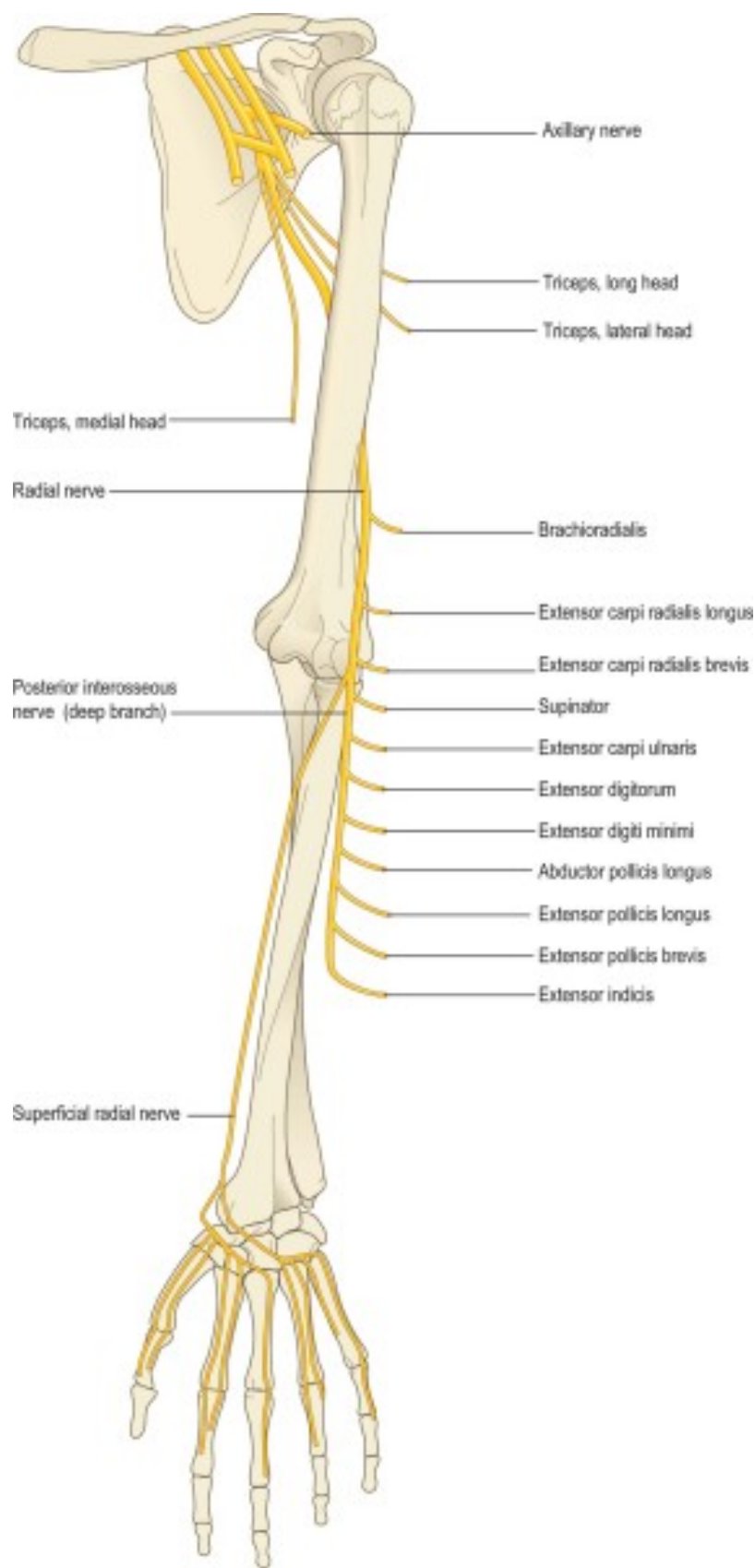
Posterior divisions of the trunks and their derivatives

Fibres from C7 that contribute to the ulnar nerve

Posterior Forearm and Hand: Skeleton



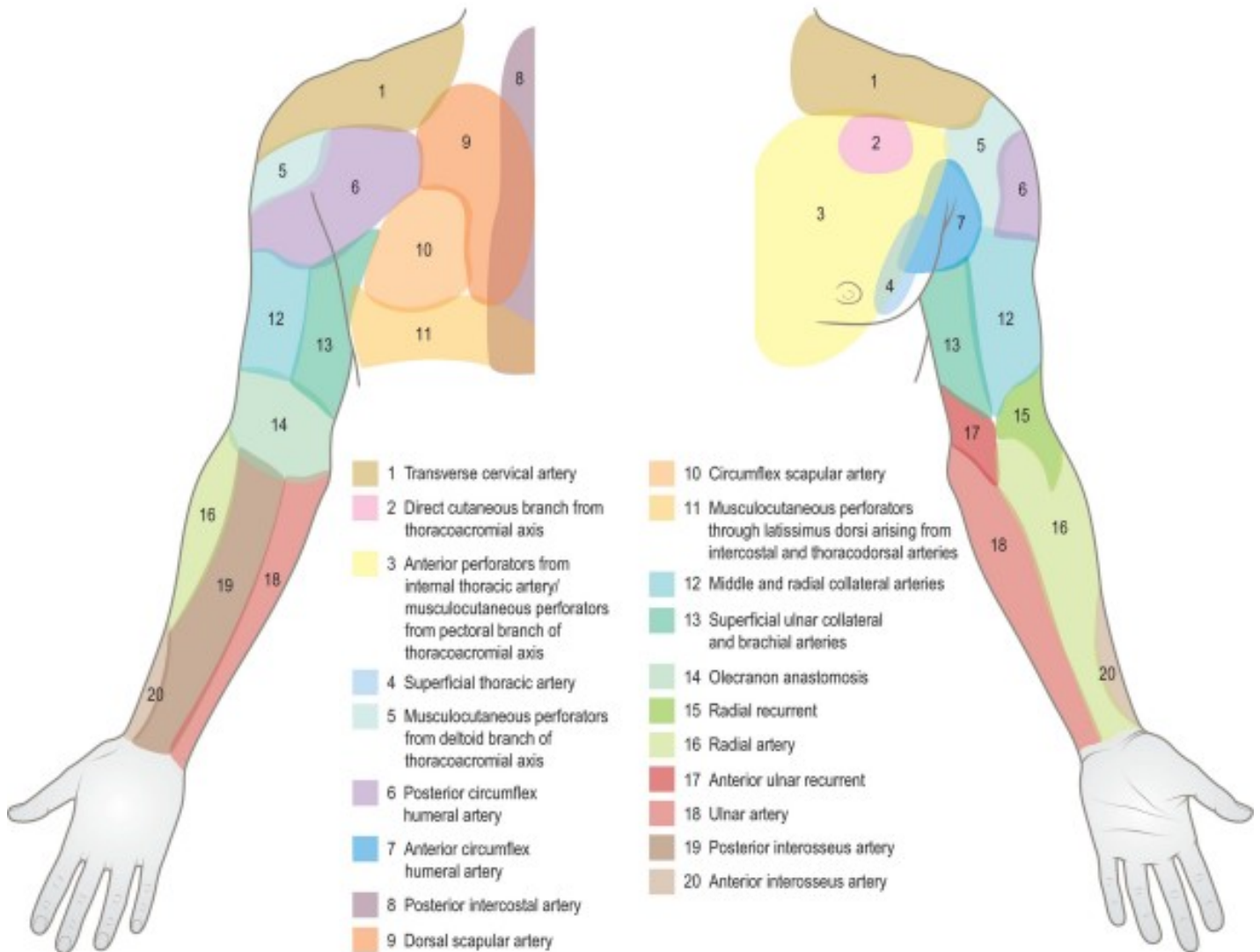
Posterior Forearm and Hand: Radial Nerve Distribution



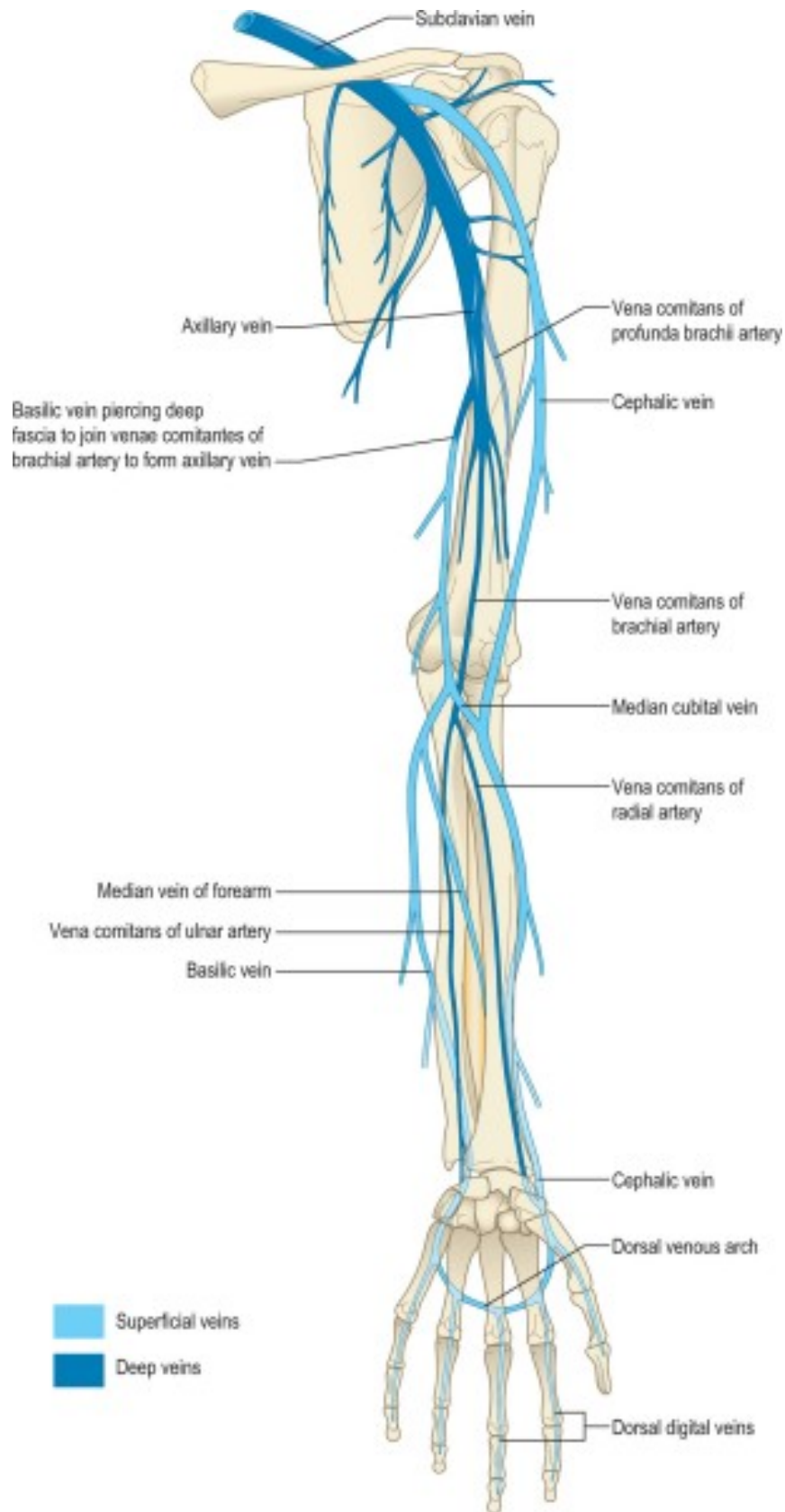
Posterior Forearm and Hand: Arterial Supply

A Posterior

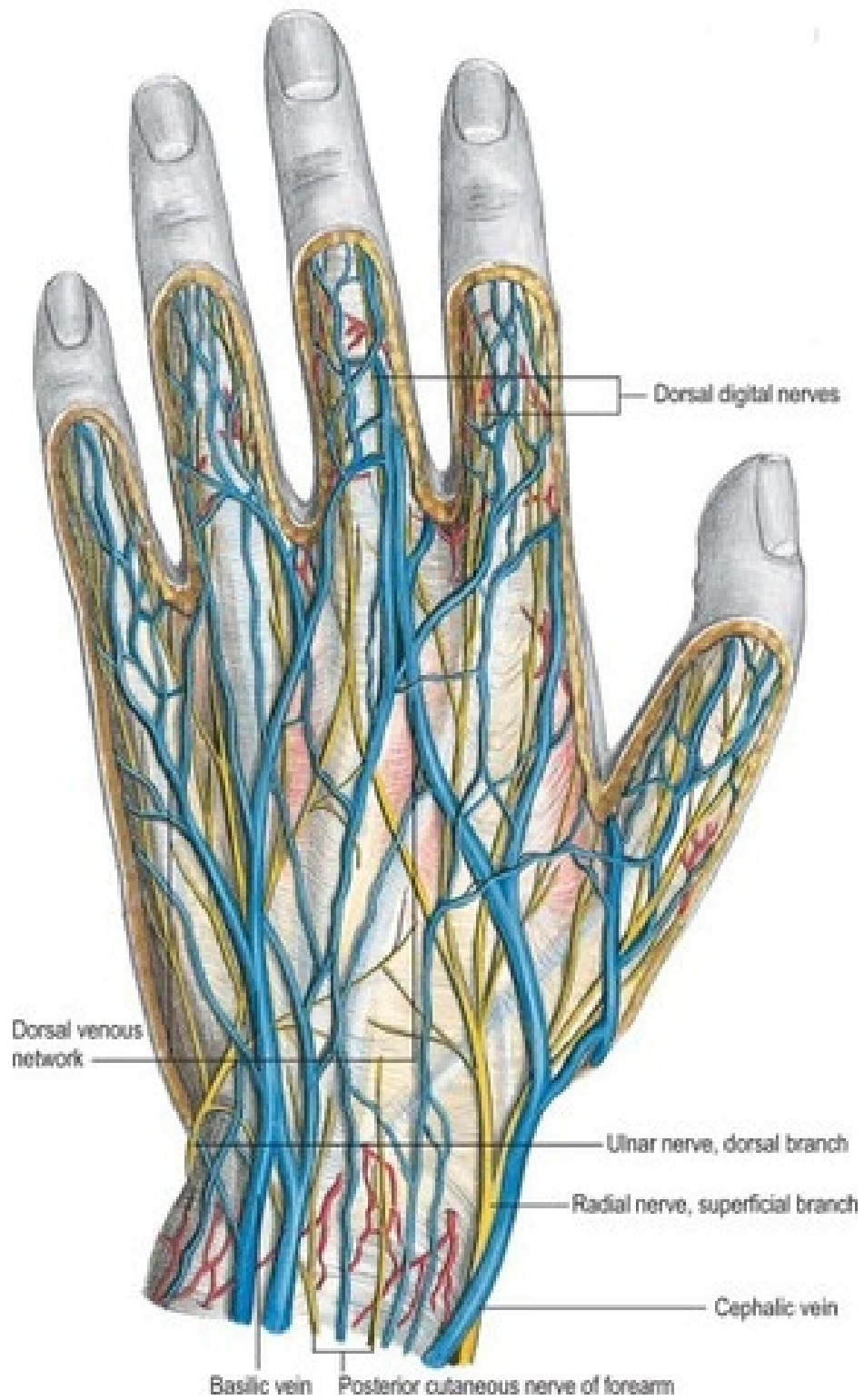
B Anterior



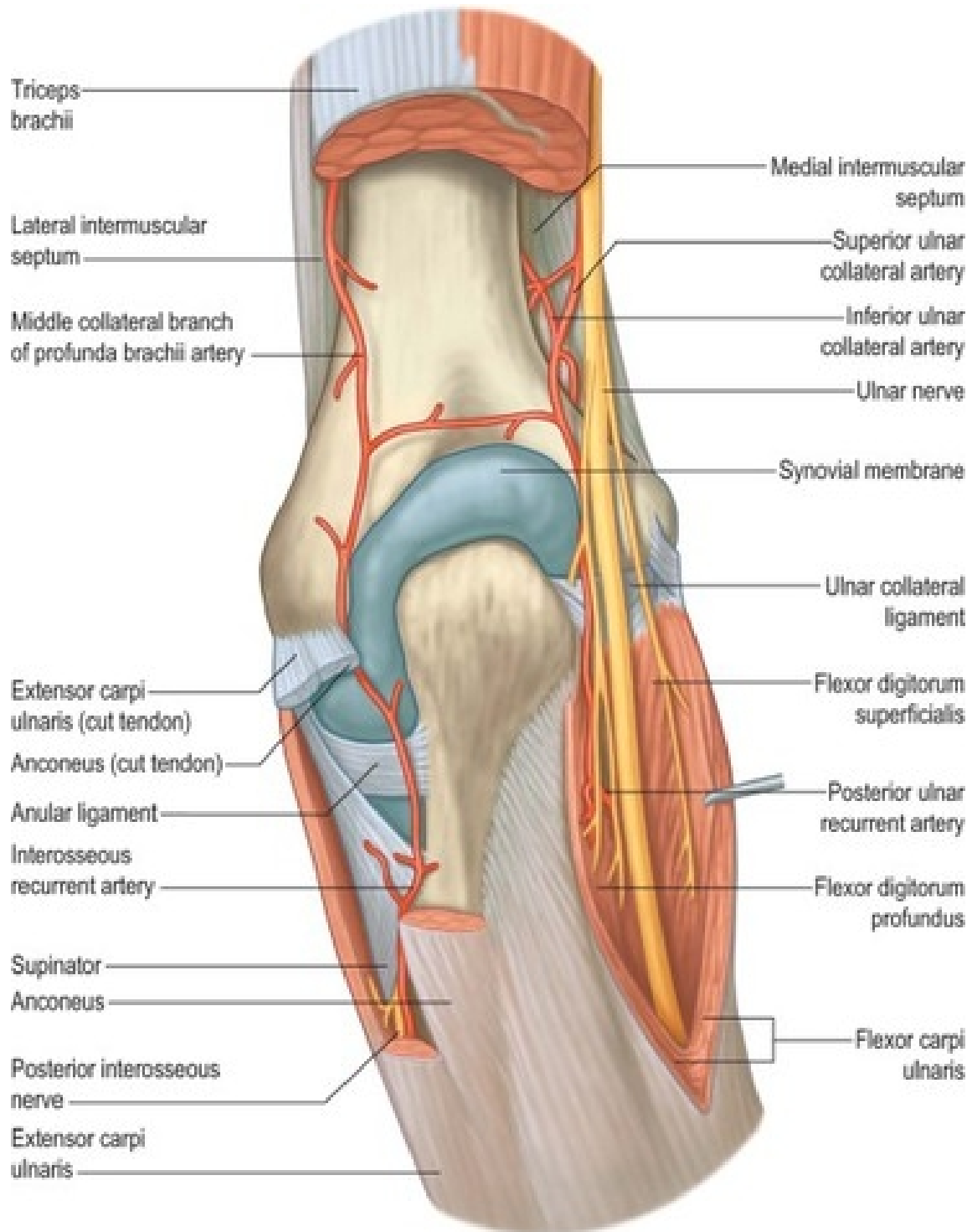
Posterior Forearm and Hand: Venous Supply



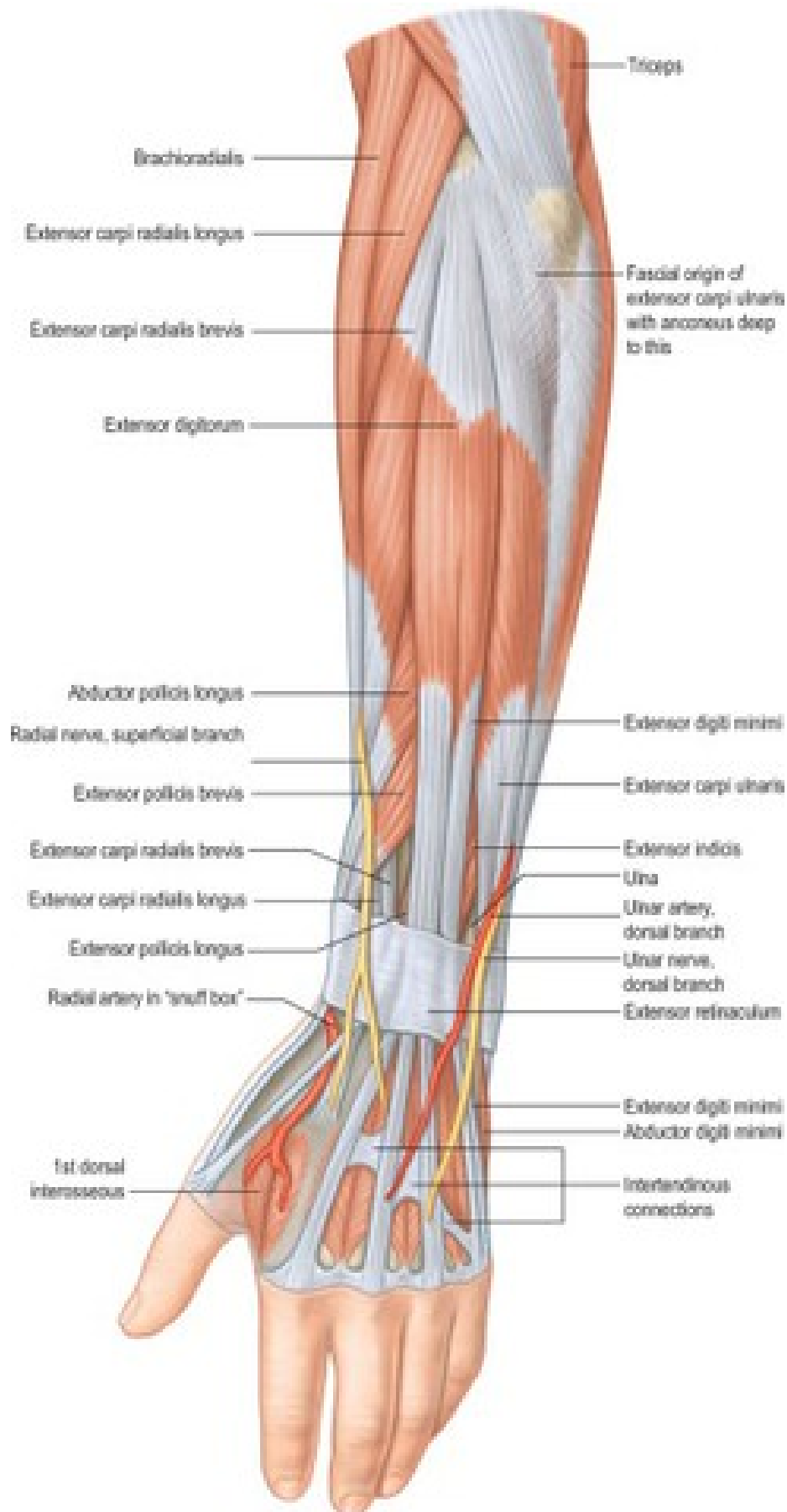
Posterior Forearm and Hand: Venous Supply



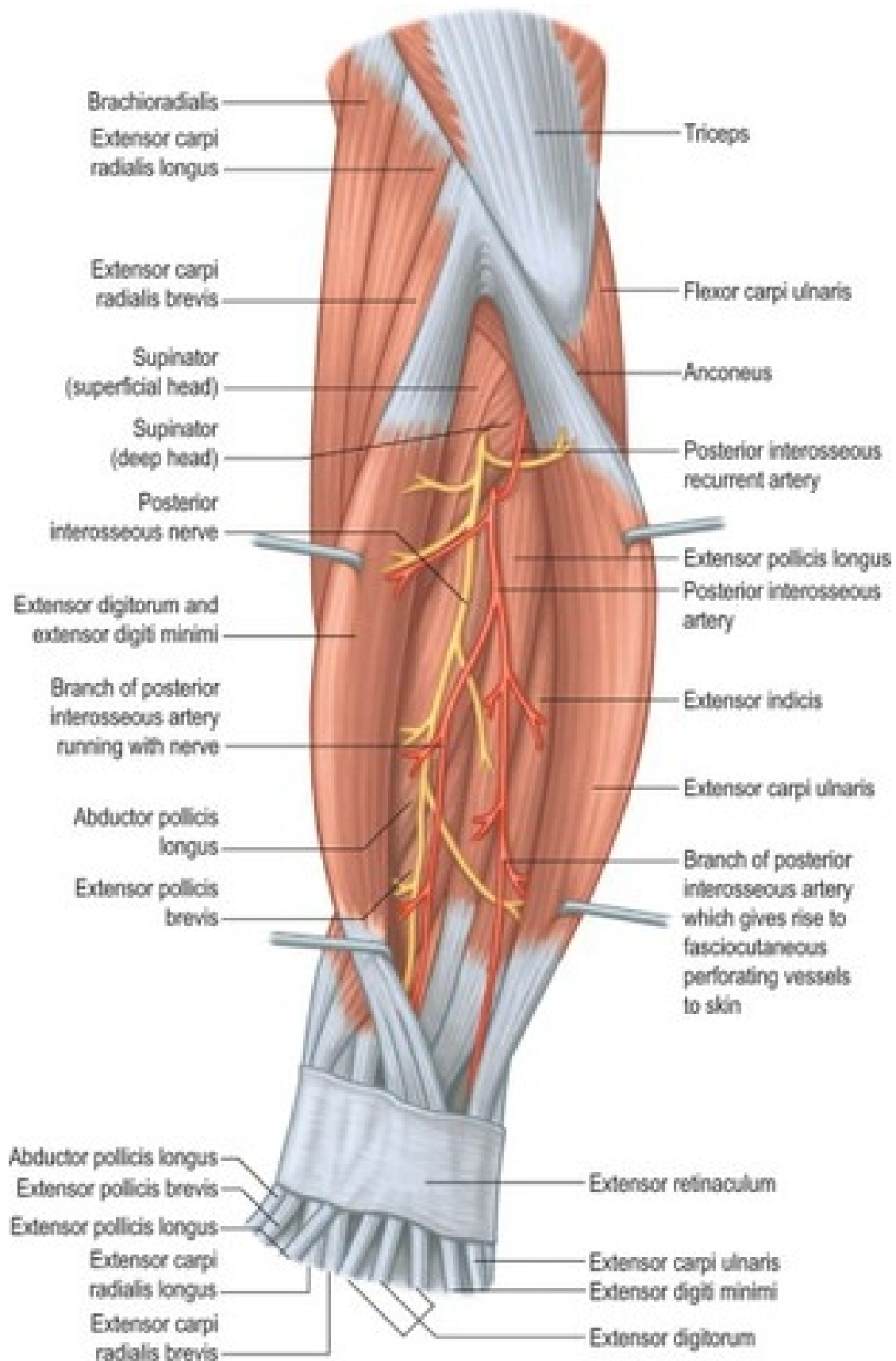
Posterior Forearm and Hand: Elbow



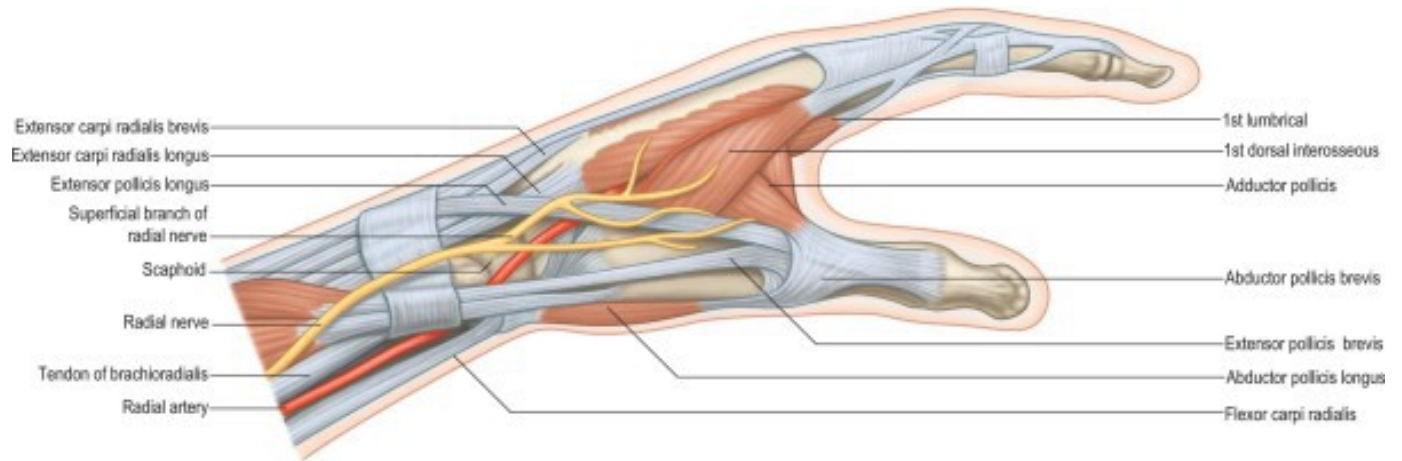
Posterior Forearm and Hand: Muscles



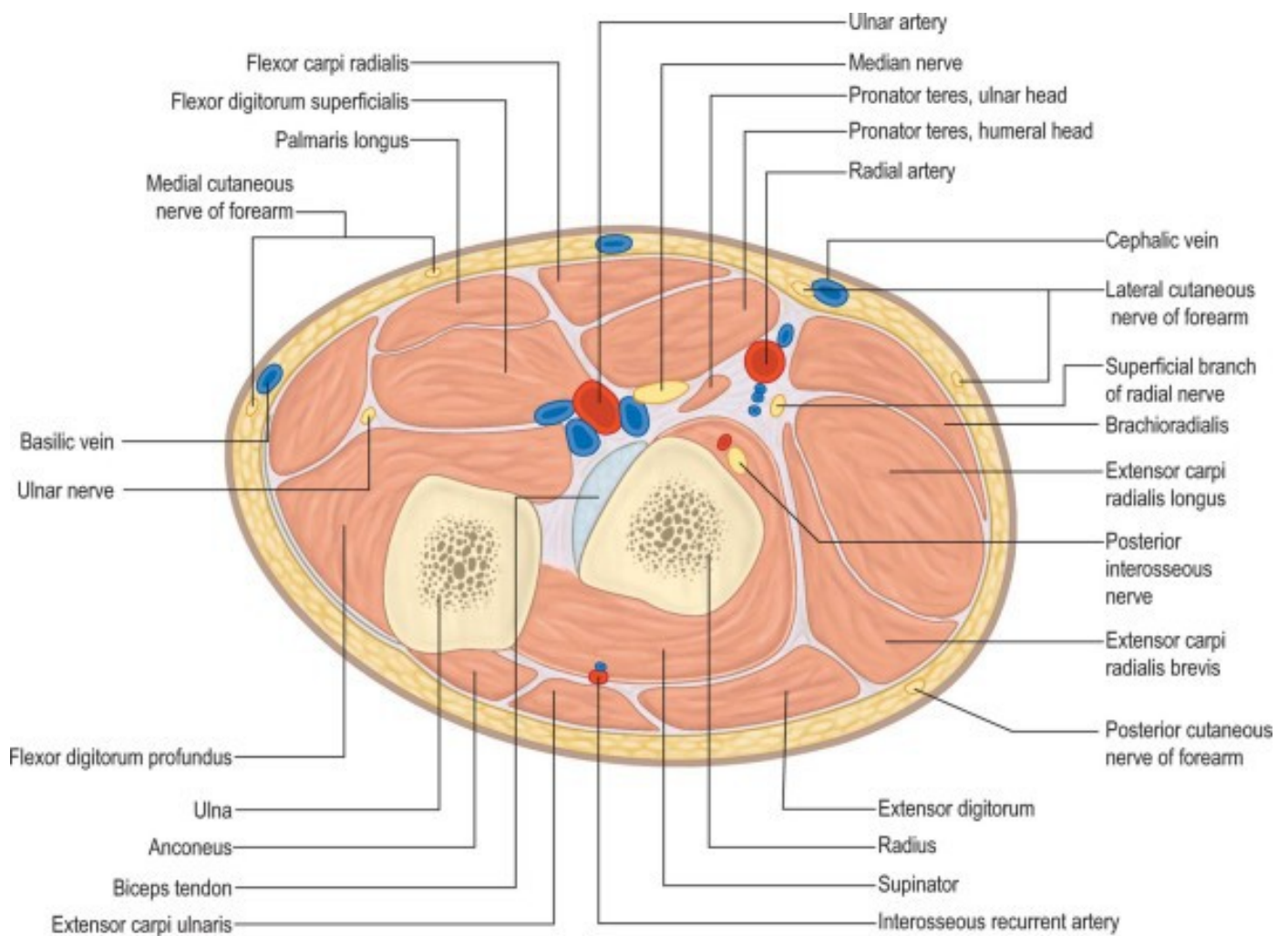
Posterior Forearm and Hand: Muscles



Posterior Forearm and Hand: Anatomical Snuffbox



Posterior Forearm and Hand: Cross Sections



Posterior Forearm and Hand: Cross Sections

